




**ISSN : 2347-2251**

**Indo-American Journal of  
Pharma and Bio Sciences**



[www.iajpb.com](http://www.iajpb.com)

[iajpb.editor@gmail.com](mailto:iajpb.editor@gmail.com)  
[editor@iajpb.com](mailto:editor@iajpb.com)



## Allergic bronchopulmonary aspergillosis is an extremely uncommon cause of acute respiratory failure.

Mr. T VENKATESWARA RAO , Mr. B SRIKANTH REDDY , Mr. JAYA PRAKASH V

Associate Professor<sup>1,2</sup> Asst Prof<sup>3</sup>

M.PHARMACY- Pharmaceutics<sup>1,2</sup>, M.PHARMACY-Pharmaceutical Analysis<sup>3</sup>  
Nimra College of Pharmacy, Jupudi, Krishna District, Andhra Pradesh-521456.

### ABSTRACT

In individuals with asthma and cystic fibrosis, allergic bronchopulmonary aspergillosis (ABPA) is a common complication caused by a complicated immunological hypersensitivity response to *Aspergillus fumigatus*.<sup>1</sup> Breathlessness, bronchiectasis, and mucoid impaction are frequent radiographic findings.<sup>1</sup> Case presentation of a 40-year-old guy with severe hypoxaemic respiratory failure is reported here. After additional testing, the diagnosis of ABPA was confirmed.

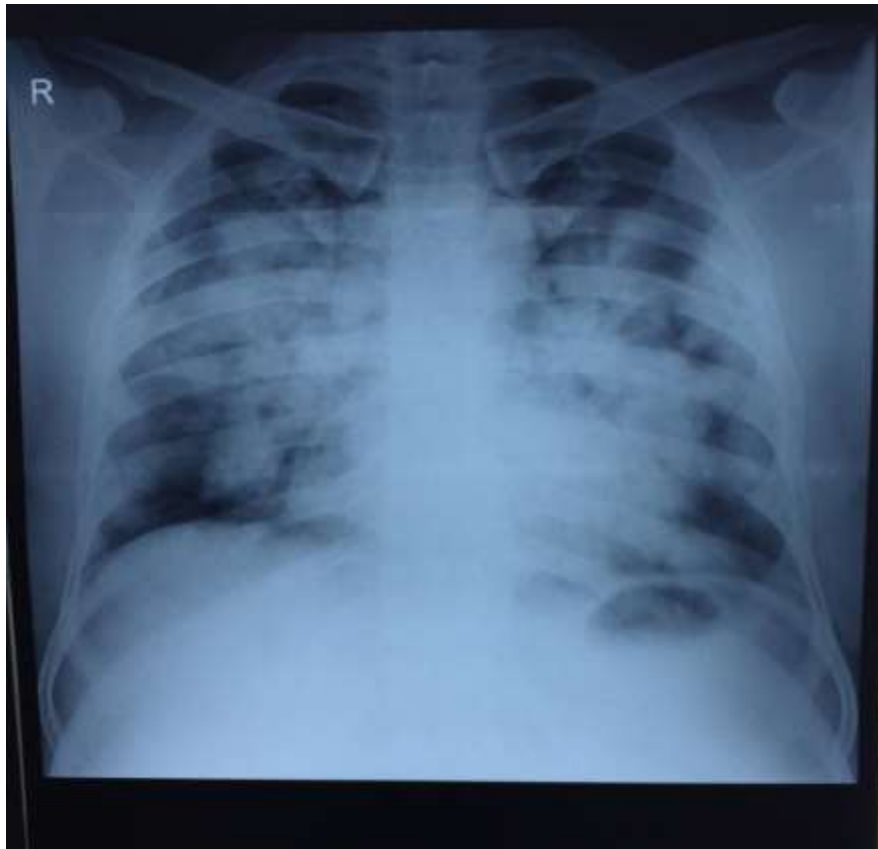
### INTRODUCTION

A hypersensitive response to antigens of the *Aspergillus* species, most often those of *Aspergillus fumigatus*, causes allergic bronchopulmonary aspergillosis (ABPA). In 1952, Hinson et al. were the first to describe ABPA. Patients with allergic disorders, such as asthma or cystic fibrosis (CF), are disproportionately affected by ABPA.<sup>4</sup> C.O.P.D.<sup>5</sup>, low body mass index<sup>6</sup>, long-term use of corticosteroids, reduced immunological response, chemotherapy, and organ transplantation are all potential contributors.<sup>7</sup>

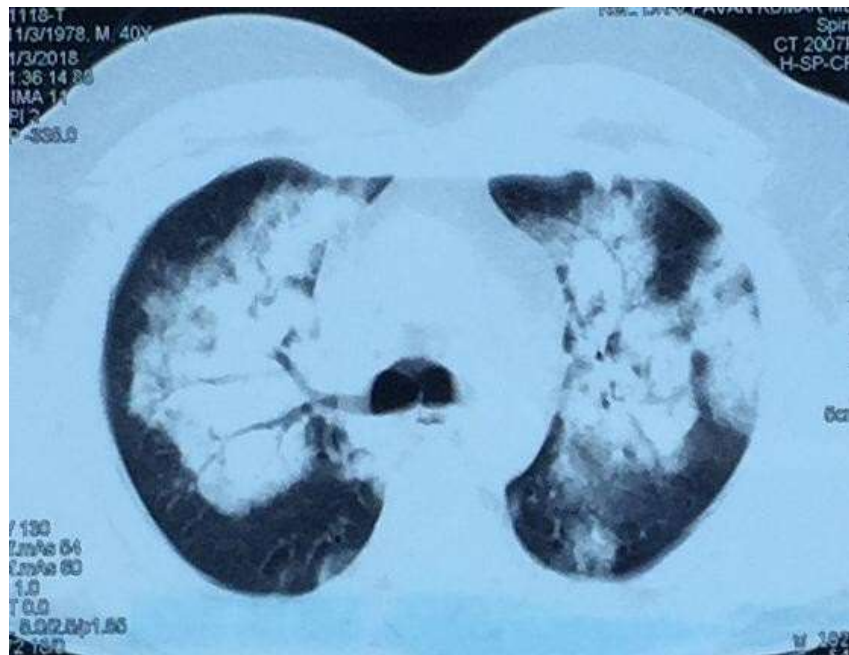
### CASE REPORT

A 40-year-old male truck driver with no history of respiratory disease came to the emergency room complaining of shortness of breath and a cough that had lasted for a week. He also had mucoid expectoration. In only 7 days, your shortness of breath went from mild to severe. There was no prior history of hemoptysis, chest discomfort, wheezing, high body temperature, vomiting, or a decrease in appetite. He has no associated medical conditions. Patient was alert, aware to time and location, and had a resting heart rate of 125 beats per minute and a respiratory rate of 37 breaths per minute with a blood pressure of 110 over 80 mm Hg. We found no evidence of pedal edema, lymphadenopathy, clubbing, jaundice, or icterus. There was no increase in the venous pressure in the jugular vein. When the patient's chest was auscultated, a polyphonic wheeze was heard from both sides. Radiology of the chest showed opacities around the hila. Type 1 respiratory failure was suspected based on arterial blood gas results (pH = 7.44, PaO<sub>2</sub> = 46 mmHg, PaCo<sub>2</sub> = 20 mmHg, HCO<sub>3</sub> = 21 mmol/L). There were air bronchograms and hyperdense opacities around the bronchi on the HRCT of the chest. After intubation, a fiberoptic bronchoscopy showed mucus plugs and

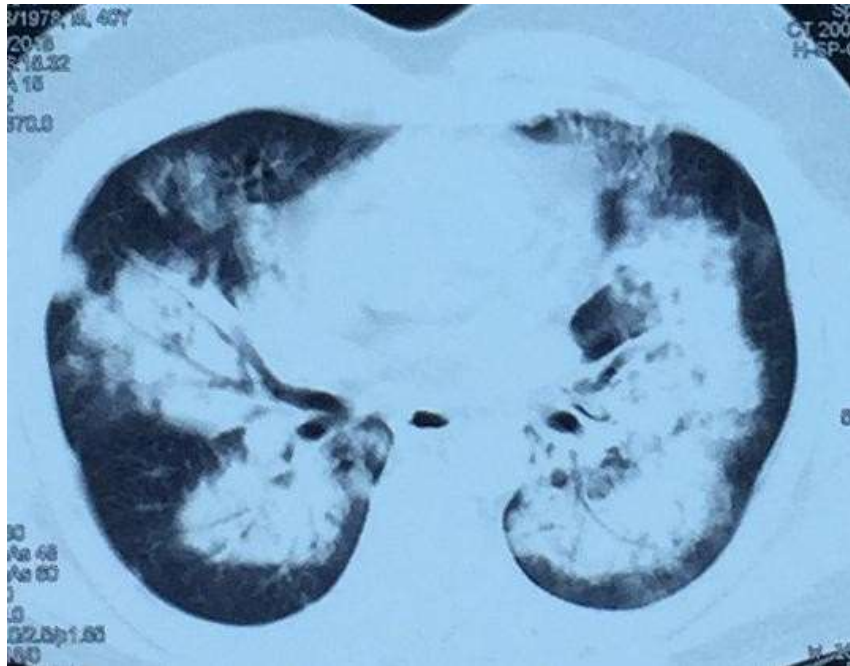viscous secretions in both the right and left major bronchi. The secretions from a therapeutic bronchoalveolar lavage were submitted for gram staining, culture sensitivity testing, fungal staining, and fungal cultures. Bacterial cultures were negative, and a KOH wet mount revealed septate hyphae and the growth of *Aspergillus fumigatus* in a fungal culture. There was an increase in both total IgE in the serum (2300 IU/ml) and IgE directed towards *aspergillus* (13.2 kUA l-1). The *aspergillus* antigen skin test revealed cutaneous hyper reactivity (12mm induration). The patient was given prednisolone 40 mg daily once a definitive diagnosis of allergic bronchopulmonary aspergillosis was obtained. The patient's symptoms had subsided and the radiological diagnosis had been resolved after 4 weeks.



**Figure 1:** Chest radiograph showing bilateral perihilar homogenous opacities

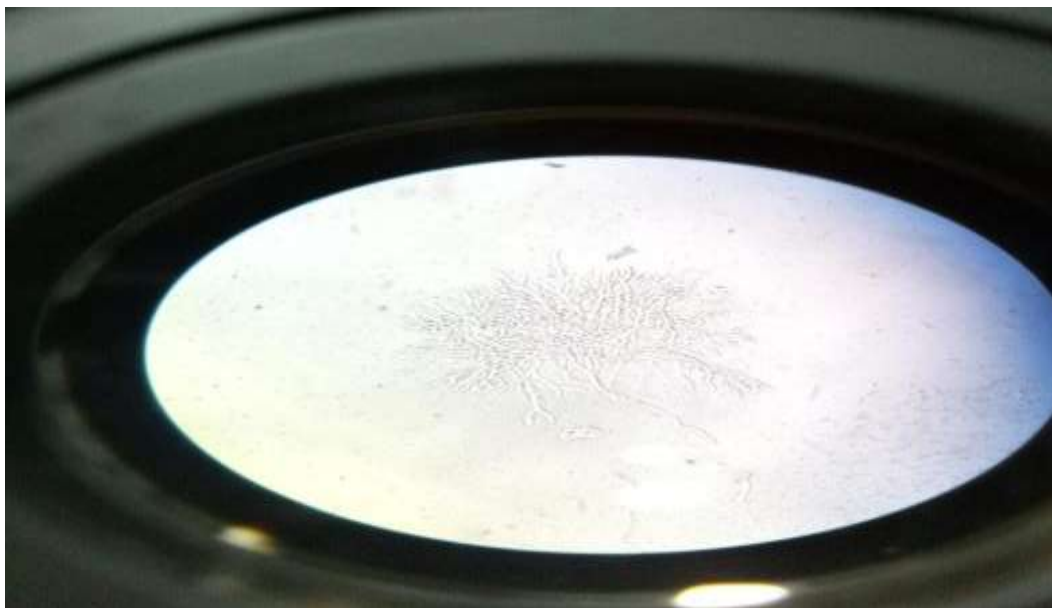


**Figure 2**

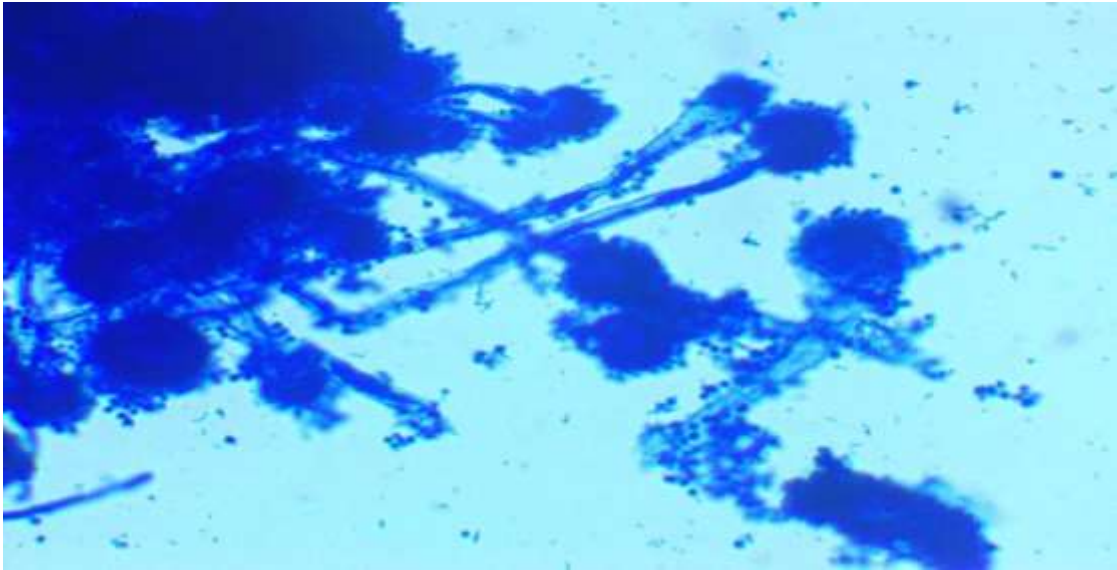


**Figure 3**

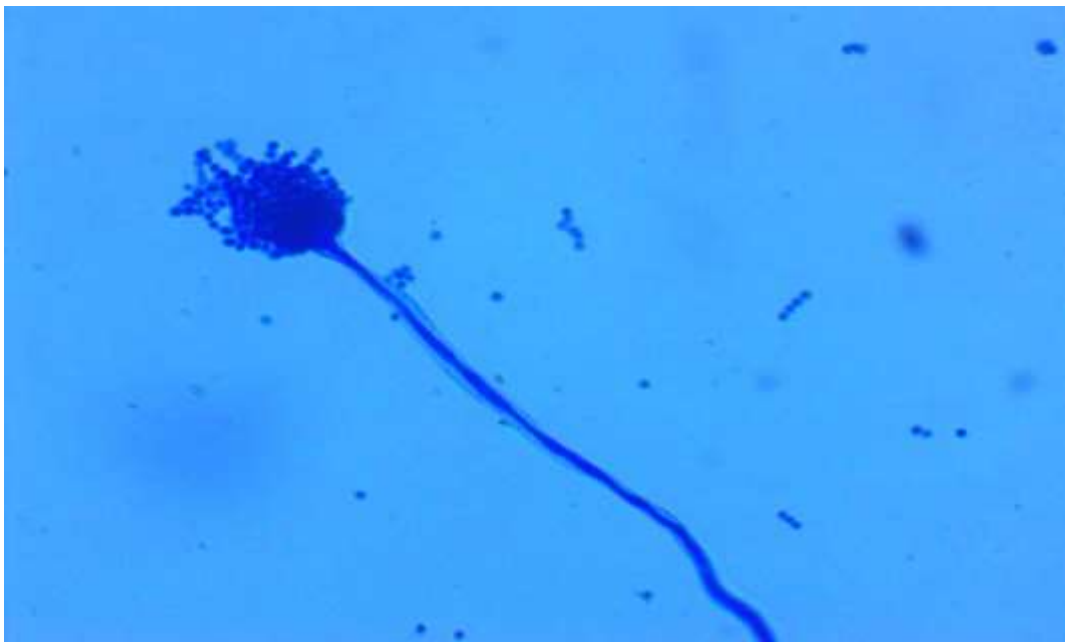
**Figure 2 & 3 :** HRCT showing Peri bronchial hyperdense opacities with air bronchogram



**Figure 4:** Potassium Hydroxide(KOH) wet mount showing branching hyphae

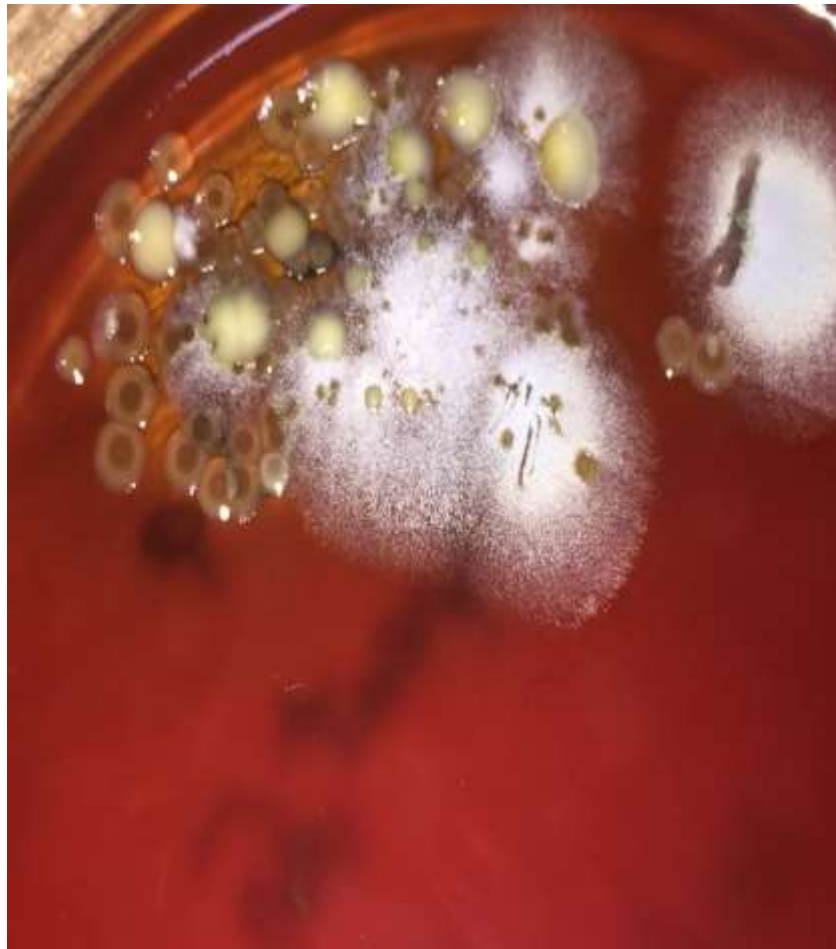

**Figure 5**



**Figure 6**

**Figure 5 & 6:** Lactophenol cotton blue mount showing *Aspergillus fumigatus* phialides and conidia extend from the top of the vesicle.



**Figure 7:** *Aspergillus fumigatus* colonies on Blood agar plate .

## I. DISCUSSION

An allergic inflammatory response to fungal colonization of the airways characterizes allergic bronchopulmonary aspergillosis (ABPA), an idiopathic inflammatory illness of the lungs.<sup>8</sup> Some of the unusual manifestations of ABPA include: In 1982, Berkin et al. reported four individuals with a final diagnosis of ABPA<sup>9</sup> with either total or partial atelectasis in the absence of a history of asthma. In 2006, Agarwal et al. reported on the case of a 60-year-old woman who was diagnosed with ABPA after being examined for a widening of the left hilum on chest x-ray.<sup>10</sup> The primary treatment for ABPA is not antifungal medicine directed at the fungus itself, but rather systemic corticosteroids to decrease the allergic reaction. The standard treatment for ABPA is currently oral corticosteroids.

A truck driver who hauls bamboo from the forest to the paper mill is our unfortunate patient. Contamination by *Aspergillus fumigatus*

several types of trees used in agriculture, including wood and fruit trees. Molded materials release allergens into the air when handled, including spores, mycelium pieces, and fungal metabolites. Bilateral perihilar homogeneous opacities and severe respiratory failure are new presentations of ABPA.

## REFERENCES

- [1]. Researchers Agarwal, Aggarwal, Gupta, and Gupta, PhD. Allergic bronchopulmonary aspergillosis is an extremely unusual cause of severe respiratory failure. [2] *Mycoses*, 2011, 54, e223-6. These four people are all named Pooja Aneja: Balwinder Kaur, Kalpesh Patel, Urvinder Pal Singh. *Aspergillus milaris*: a rare manifestation of allergic bronchopulmonary disease. Page 285–288 in *Lung India*, Issue 31 (July–September 2014).

Three authors; Hinson KF, AJ Moon, and NS Plummer. A discussion on bronchopulmonary aspergillosis

along with the announcement of eight further instances. Published in *Thorax* 7 (1952):317–33.

Polubiec-Kownacka, M., Jakubowska, L., Wiatr, E., and Nowicka, U. A case report of a female patient who did not have asthma but who was diagnosed with allergic bronchopulmonary aspergillosis, which resembled lung cancer. 2012;80:77-81 *Pneumonol Alergol Pol*.

[5] Agarwal, R.; Hazarika, B.; Gupta, D.; Aggarwal, A. N.; Chakrabarti, A.; Jindal, S. K. Aspergillus hypersensitivity in COPD patients: is COPD a risk factor for allergic bronchopulmonary aspergillosis? 2010;48:988-94. *Med Mycol*.

V. Jubin, S. Ranque, N. Stremler Le Bel, J. Sarles, and J. C. Dubus are the authors of Reference 6. Children with cystic fibrosis are at risk for Aspergillus colonization and allergic bronchopulmonary aspergillosis. 2010;45:764-771 *Pediatr Pulmonol*.

Epidemiology and risk factors for invasive aspergillosis in nonneutropenic individuals. [7] Gangneux JP, Camus C, Philippe B. The citation for this article is *Rev Mal Respir* 2008;25:139-53.

Fishman's Pulmonary Disorders, 5th Edition [8]. Michael A. Grippi is the chief editor. Allan I. Pack, Robert M. Senior, and Jack A. Elias, Jay A. Fishman, and Robert M. Kotloff served as editors. Mark D. Siegel is the video editor. There were 278 writers from 12 different nations. McGraw-Hill Medical, New York, 2015. It has a 978-0071807289 ISBN-13 and a 0071807284 ISBN-10.

[9]. Lung collapse due to allergic bronchopulmonary aspergillosis in individuals without a history of asthma. It was published in the *British Medical Journal* in 1982, on pages 552–53.

[10]. An uncommon cause of hilar lymphadenopathy. Agarwal R, Reddy C, Gupta D. Reference: *Lung India* 2006;23:90-2.